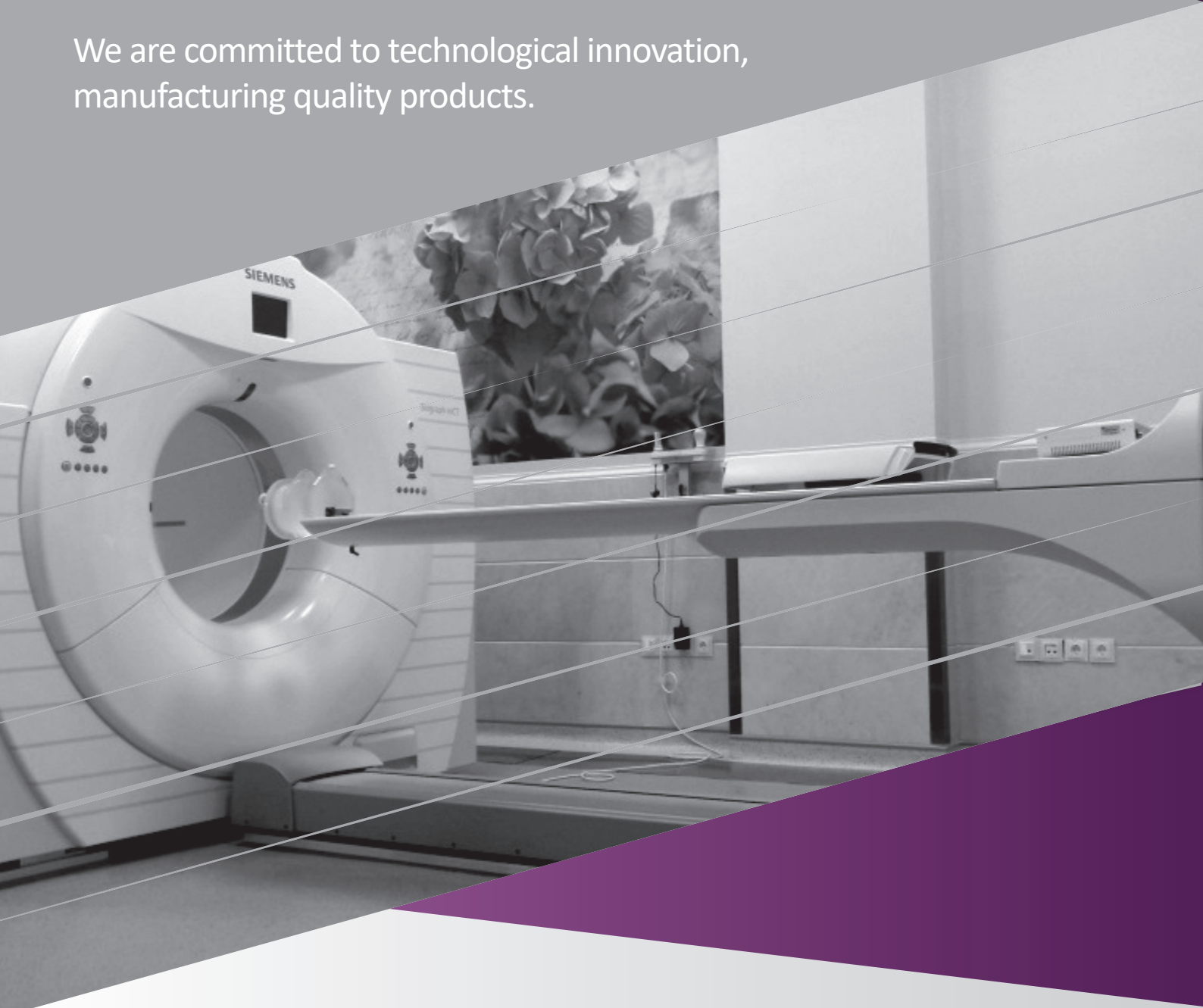



# PET/CT Scan In Breast Cancer

We are committed to technological innovation,  
manufacturing quality products.



**Prepared By:**

- Forough kalantari
- Reza vali
- Zohreh adinepour
- Alireza rezaiee

# PET/CT scan in Breast Cancer

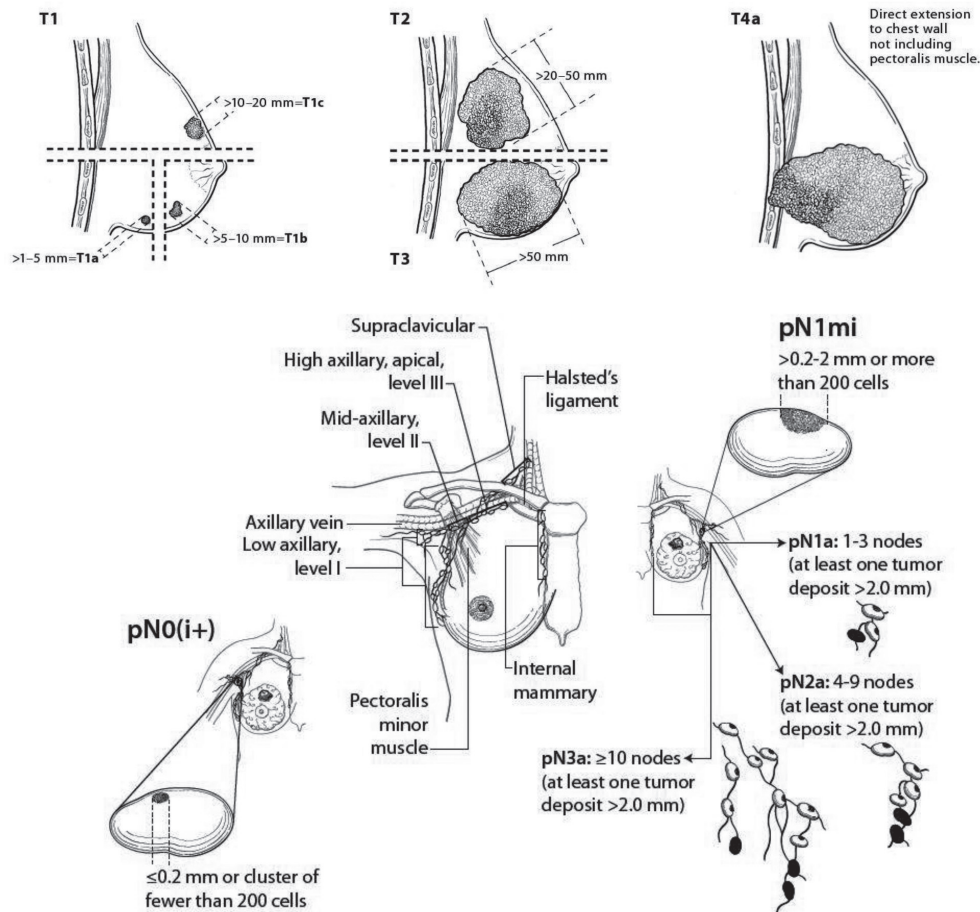
## Combined anatomic and physiologic imaging

Cancer is a major cause of morbidity and mortality in both developing and developed countries. Breast cancer is the fastest growing cancer in women; the incidence has increased with an annual rate of 3.1%. Although Iran is not among the top 10 countries with the highest number of breast cancers, it is still the first cancer among Iranian women (both in cancer incidence and cancer mortality profile). Genetic mutation, higher lifetime exposure to hormones, obesity, having dense breasts, family history, drinking alcohol, and smoking, are the suggested risk factor for breast cancer.

Traditional TNM factors plus taking into account the non-anatomic and biologic factors (tumor grade, HER2, hormone receptor status (ER, PR) made the last (8th) edition of AJCC prognostic stage group. Application of prognostic stage assigns almost 41% of cases to different groups (better or worse). The TNM staging is summarized in figure 1.

Figure 1. TNM staging in breast cancer

ANATOMIC STAGE			
Stage 0	Tis	N0	M0
Stage IA	T1	N0	M0
Stage IB	T0	N1mi	M0
	T1	N1mi	M0
Stage IIA	T0	N1	M0
	T1	N1	M0
Stage IIB	T2	N0	M0
	T2	N1	M0
Stage IIIA	T0	N2	M0
	T1	N2	M0
	T2	N2	M0
	T3	N1	M0
Stage IIIB	T3	N2	M0
	T4	N0	M0
	T4	N1	M0
Stage IIIC	T4	N2	M0
	Any T	N3	M0
Stage IV	Any T	Any N	M1



## The value of FDG PET/CT

PET/CT is most helpful in situations where the standard staging studies are equivocal or suspicious especially in the setting of a locally advanced or metastatic disease. FDG PET/CT may also be helpful in identifying unsuspected regional nodal disease and/or distant metastasis in locally advanced breast cancers in addition to standard staging studies.

### Staging

- Staging of locoregional and distant disease affects management.
- Hybrid PET/CT imaging leads not only to upstaging but also sometime to down staging of cancer.
- Use of FDG PET at initial staging might be appropriate with clinical stage II B and primary operable stage III A.
- In node positive stage II and III groups, bone scan and contrast enhanced CT of the chest and abdomen should be perform.
- For stage IV or recurrent disease FDG PET is very sensitive and specific.
- FDG PET reveals occult site of malignancy and demonstrate more lesions than conventional imaging which leads to improve staging and therapeutic options.
- There is a correlation between tumor proliferation index (ki 67) and intensity of FDG uptake, as well as estrogen and progesterone negative tumors and breast cancers with p53 mutation that associated with poorer patient outcome.
- Sentinel lymph node biopsy has higher sensitivity for axillary nodal staging in early stage breast cancer. However, in high risk patients with high likelihood of axillary metastasis, in locally advanced breast cancer, and for distinguishing radiation plexopathy from recurrence, FDG PET has a higher sensitivity.
- Sensitivity of FDG PET is superior to CT scan alone for the assessment of tumoral spread to internal mammary nodes.

### Restaging

- In patients with clinical symptoms/ radiologic finding/ biological marker (CA153-/CEA) suggestive of recurrence, PET/CT is superior to conventional imaging; particularly in restaging of focally recurrent disease if aggressive local therapy is being considered.
- PET may demonstrate unsuspected mediastinal or distant metastatic disease that would change the clinical management.
- When a recurrence is depicted or suspected by conventional imaging; PET/CT can determine if the recurrence is isolated or not.
- Evaluation of asymptomatic breast cancer with rising levels of tumor markers.

### Summary

#### In Staging-restaging, FDG/PET is:

- Promising staging modality for
  - primary tumor >3 cm
  - Recurrent disease
- When other conventional studies are equivocal or suspicious

## Assessment of response to treatment

- Neoadjuvant chemotherapy is the first treatment for non-operable locally advanced and inflammatory breast cancers and commonly used for operable large tumors to increase the chance of successful surgery.
- Early prediction during neoadjuvant chemotherapy offers early opportunity to change strategy in case of ineffectiveness, so stopping ineffective chemotherapy could avoid unwanted side effects.

## Monitoring metastatic disease

- PET/CT study is optional as a baseline prior to new therapy, prior or interim cycles of chemotherapy and in case of suspected progression.
- Bone scan or sodium fluoride PET/CT is recommended by National Comprehensive Cancer Network (NCCN) for detection of bone metastases. However, if FDG PET clearly indicates bone metastasis, fluoride scan can be omitted.

## Evaluating treatment of recurrent or metastatic disease

- FDG PET/CT is accurate to depict response to treatment which might be detected as early as a single cycle of chemotherapy.
- Changes in FDG uptake have a prognostic value.
- FDG PET/CT scan can be useful to evaluate the response to therapy in bone/bone marrow metastases. Bone scan, MRI and CT are effective to identify skeletal involvement but cannot accurately assess the response to therapy.
- Skeletal metastases are the most common site of distant disease in breast cancer. FDG PET/CT is complementary to bone scan in detecting lytic and intramedullary metastasis and it is helpful in clarifying difficult or equivocal cases.
- Combination of FDG and fluoride PET/CT depicts both sclerotic and lytic lesions.

## Monitoring response to therapy

- Extent of residual disease in breast and axillae is prognostic for the disease-free and overall survival.
- Serial FDG PET/CT is a useful method for assessing tumor response to neoadjuvant systemic chemotherapy (NST). Before therapy and then at two or more time points (early, mid therapy and after therapy).
- Defining the extent of disease may affect post-surgical treatment, such as radiation therapy, by demonstrating occult nodal or distant metastatic disease.
- Decline in primary tumor FDG uptake by approximately 50% or more is predictive of a good response to NST; best assessed after two courses of chemotherapy.
- PET can demonstrate the therapy response sooner than conventional techniques which is most helpful as an early marker for the detection of resistance to therapy.

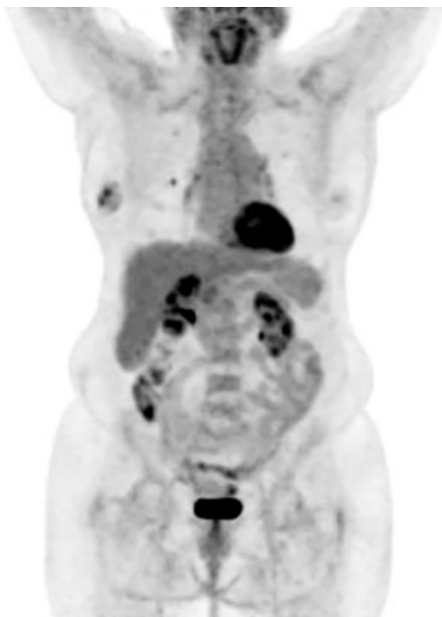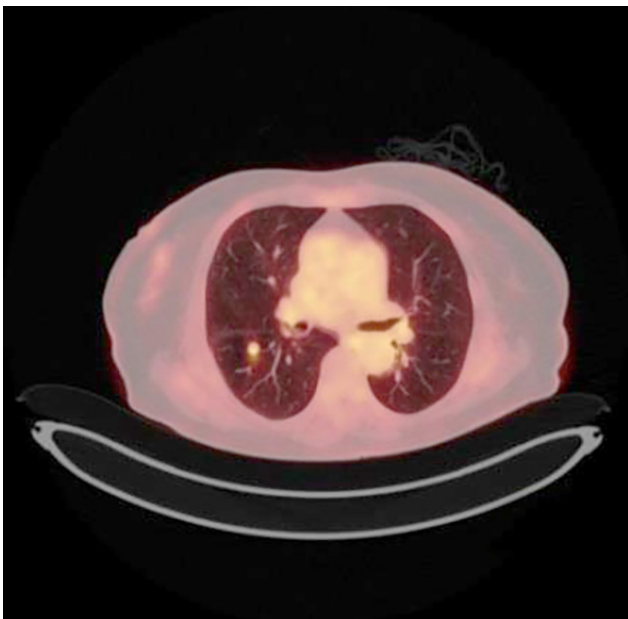## Prognostic value

- FDG avidity is considerably higher in ER negative than in ER positive as well as in triple negative breast tumors.

# Case Presentations

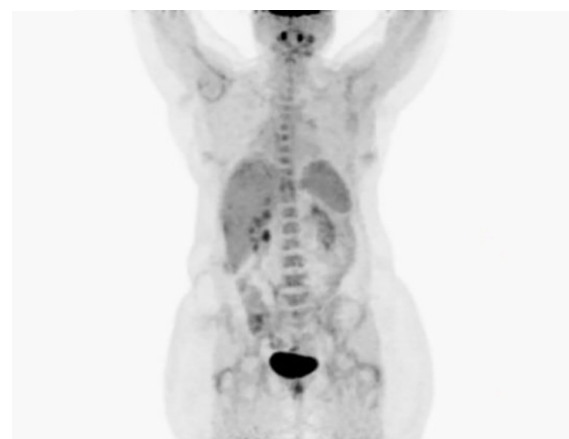
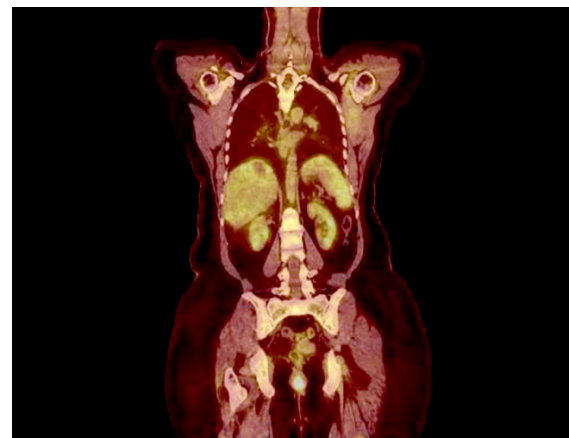
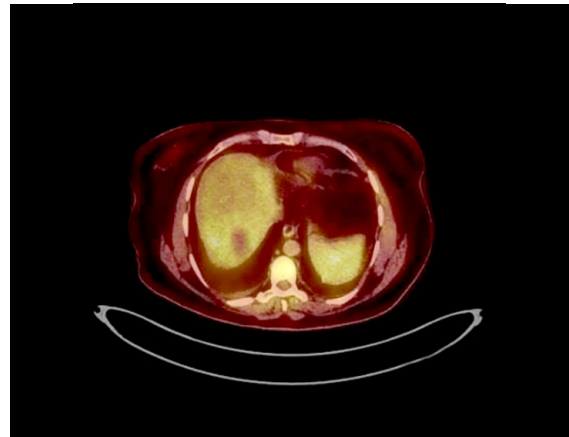
**Case 1:**

Biopsy proven right breast cancer in a 78-year old woman underwent PET/CT for staging. FDG avid sub-centimetric pulmonary metastases in both lung fields.



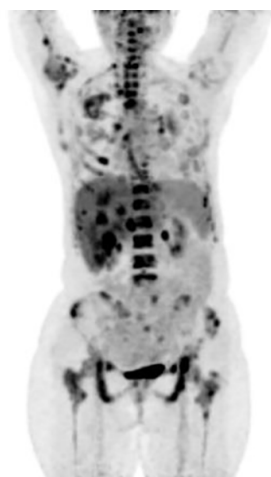
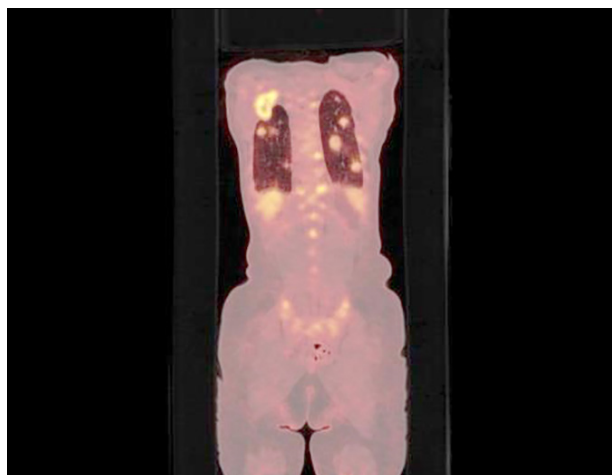
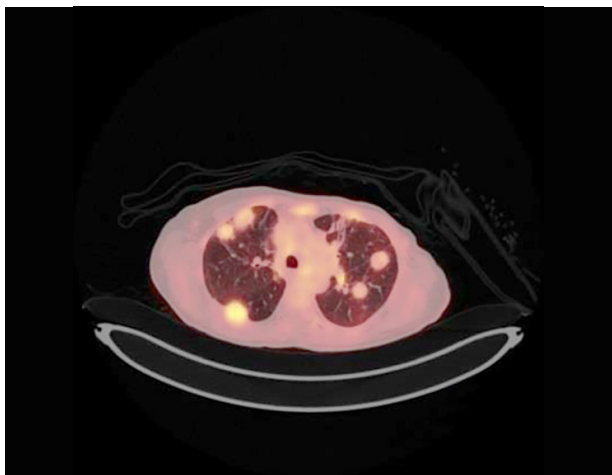
**Case 2:**

Restaging of a left breast adenocarcinoma in a 50-year old woman three years after chemotherapy and radiotherapy. While CT study shows a hypoattenuating mass, PET study reveals non-FDG avid lesion in the right liver lobe. (False positive finding in a CT scan).



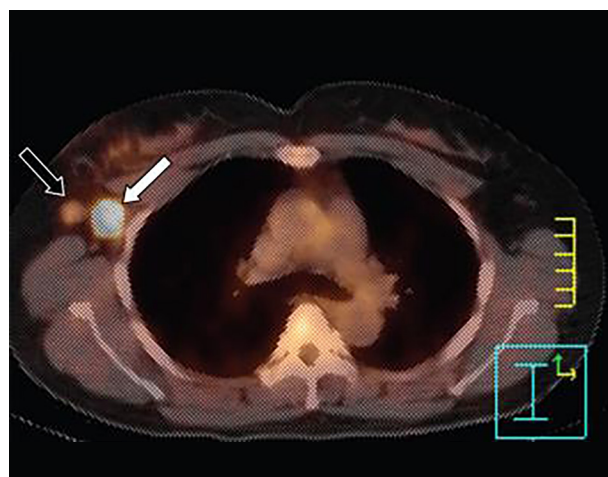
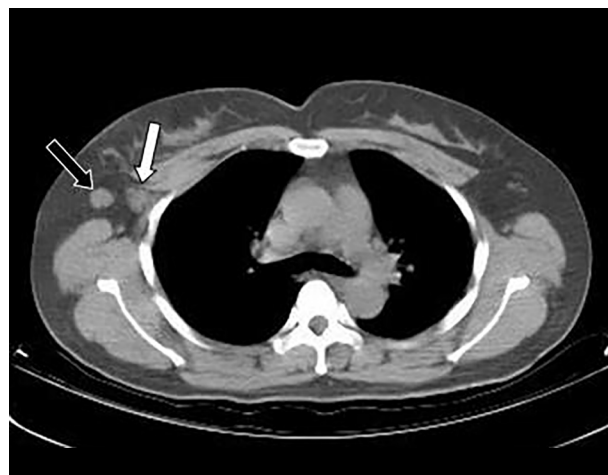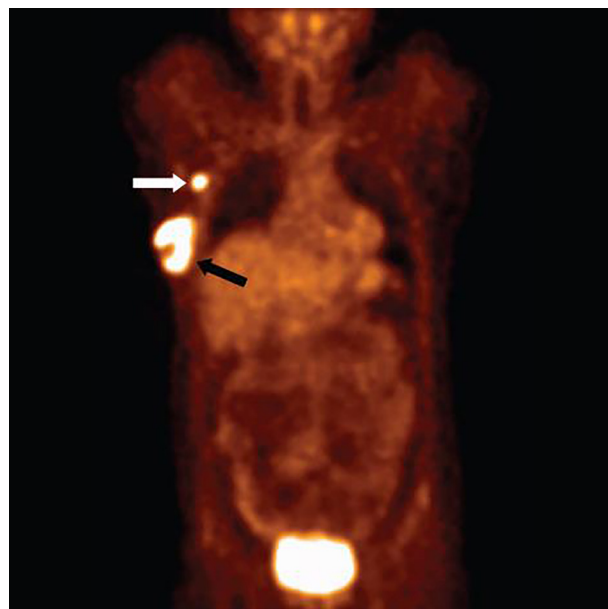**Case 3:**

Surveillance of a 59-year old woman who is a known case of breast cancer after 9 years of mastectomy, chemotherapy and radiotherapy with elevated tumor markers. Extensive metastatic lesions are evident throughout the skeleton, soft tissues and the lungs.



**Case 4:**

Axillary lymph node metastases in a 45-year old woman with right breast cancer. PET/CT shows accurate localization of the metastatic node. Surgery revealed one metastatic node out of 21 excised lymph nodes.

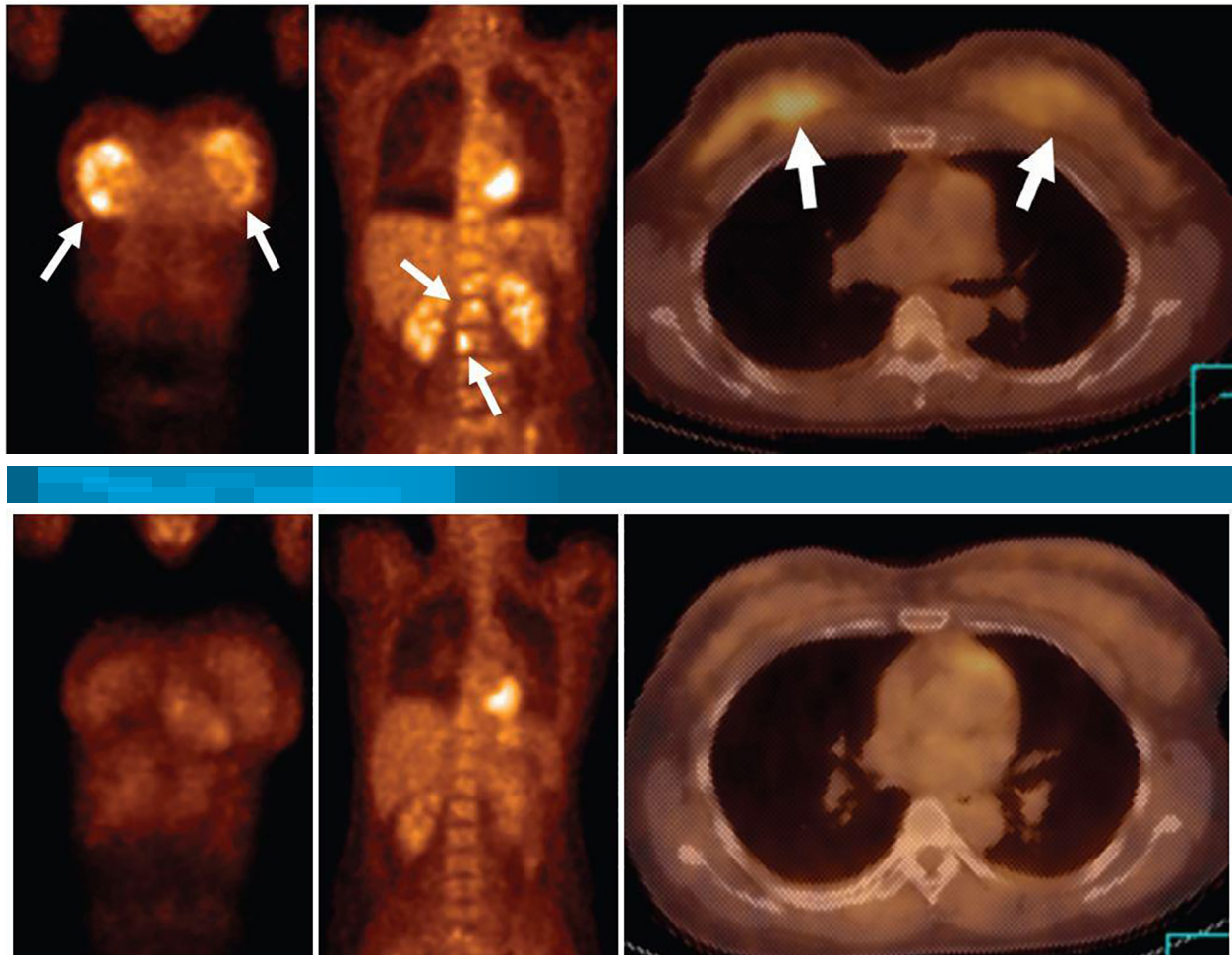


**Case 5:**

35-year old woman with bilateral breast cancer and bone metastases.

Initial FDG PET/CT with multiple metastases in the vertebrae.

Follow up PET/CT after three cycles of chemotherapy shows markedly decreased FDG uptake.

**References:**

- 1- [www.who.int/cancer/country-profiles/irn-en.pdf?Ua=1](http://www.who.int/cancer/country-profiles/irn-en.pdf?Ua=1)
- 2- International journal of pharmacy and pharmaceutical research, IJPPR Review article January 2018 vol 11 issue 2.
- 3- Sangkyu Yang, MD, Nariyacho, MD, Wookyung Mron, MD The role of PET/CT for evaluating Breast cancer Korean J Radiol 2007; 8:429437-
- 4- David Groheux, MD, Marc Espie, MD, Sylvie Giacchetti, MD et al. Performance of PET/CT in the clinical management of Breast cancer RSNA,2012; 266: 388403-
- 5- Anapaula Caresia Aroztegi, Anamaria Coarcia Vicente et al 18F-FDG PET/CT in breast cancer: Evidence-based recommendations in initial staging, tumor biology 2017: 123-
- 6- Alkem Yararbas, Neslihan Cetin Avci, et al. The value of 18F-FDG PET/CT imaging in breast cancer staging Bosn J Basic Med Sci. 2018; 18(1):7279-
- 7- Eric L.Rosen, MD. William B. E UBANK, MD, et al. 18F-FDG PET , PET/CT and breast cancer imaging RSNA,2007.
- 8- NCC N Clinical practice guild lines in oncology in breast cancer version 3.2018
- 9- American joint committee of cancer . 8th edition of Ajcc staging Manual for breast cancer 2018
- 10- Mohsen Beheshti, MD, Werner Langster MD, Alireza Rezaee MD et al PET/CT in cancer an inter disciplinary approach to individualized imaging 2018
- 11- E.Senkus, S.Kyriakides, et al . Primary breast cancer Esmo clinical practice guideline for diagnosis, treatment and follow up Annals of oncology 2015.



Address: Khatam PET/CT center, Khatam ol  
Anbia hospital, Rashid Yasemi St. , Vali- Asr Ave.,  
Tehran, 1996835911, Iran.  
Tel : +98 21 83557080 - +98 21 83557070

[www.petctkhatam.ir](http://www.petctkhatam.ir)