



KHATAM
PET/CT CENTER
www.petctkhatam.ir

Pediatric Molecular Imaging



Prepared By:

- Mahya Zarei MD,IBNM
- Reza Vali MD,MSc
- Alireza Rezaee MD,ABNM

18F-FDG PET/CT in pediatric oncology

Development of positron emission tomography/computed tomography (PET/CT), which combines a full-ring-detector clinical PET scanner with a multi-detector-row helical CT scanner, has made it possible to acquire both metabolic and anatomic imaging data with a single device in one diagnostic session, and has been demonstrated to show precise anatomic localization of suspicious areas of increased FDG uptake by malignant cells.

18 F-FDG PET/CT use in clinical settings results in significant improvement in diagnostic accuracy, with considerable impact on patient management, including diagnosis, initial staging, treatment optimization, re-staging, monitoring of response to therapy, and prognostication of various malignant tumors. We present a review of the current and future roles of FDG-PET/CT for management of common pediatric malignancies as well as its usefulness and limitation.

18F-FDG PET/CT is now a well-established modality in adult oncology imaging. Children are not just small adults and differ in their psychology, normal physiology and pathophysiology. Furthermore different tumor entities or tumor subtypes with different tumor biology may be seen in children in comparison to adults, which should be taken into account when performing PET and PET/CT in pediatrics (1). More frequently requested indication or PET imaging with F-FDG in pediatric oncology are:

- Lymphoma (HD and NHL): staging, response to therapy, restaging, assessment of residual masses after therapy, planning of radiation therapy.
- Sarcoma (osteosarcoma, ewing's sarcoma and soft tissue sarcoma, in particular, rhabdomyosarcoma): Staging, response to therapy, restaging/ detection of relapse.
- Neuroblastoma (in MIBG-negative cases or PET with specific tracers for tumors of the sympathetic nervous system).
- CNS tumors (grading, prognostic stratification, response to therapy, detection of recurrence, radiation therapy planning – other PET tracers may be used, e.g., labelled amino acids).

Less frequent indications for PET imaging in pediatric oncology include evaluation of Germ Cell tumors, hepatoblastoma, wilms tumor, malignancy of unknown primary and neurofibromatosis type 1 for suspected malignant transformation or neurofibroma (1).

Lymphoma

Introduction

Hodgkin lymphoma (HD) accounts for approximately 7 percent of childhood cancers and 1 percent of childhood cancer deaths in US. Hodgkin lymphoma is similar in adults and children (Subtypes, presentations, treatment, etc, ...). subtypes of HD are Nodular sclerosis (70%), mixed cellularity (20-25%), lymphocyte rich (5%) and lymphocyte depleted.

Non Hodgkin Lymphoma (NHL) is the fifth most common diagnosis of pediatric cancer in children under the age of 15 years and it accounts for approximately 7 percent of childhood cancers in developed world (2). Unlike in adults where low-grade clinically indolent NHL subtypes predominate, most pediatric NHL cases are of high grade and have an aggressive clinical behavior. In US and other developed countries, the most common subtypes are Burkitt lymphoma, diffuse large B cell lymphoma (DLBC), lymphoblastic T cell or B cell lymphoma and anaplastic large cell lymphoma. (3).

Staging of HD

The Ann Arbor System is still the most commonly applied staging system, although specific staging systems for distinct histologic subtypes (e.g., MALT lymphoma: Lugano Staging System, Paris Staging System) have been developed as a result of various shortcomings of the Ann Arbor Staging System, especially in primary extranodal lymphomas (2, 3,4, 5,7,11).

Stage I	Localized disease, limited to one lymph node
Stage II	Involvement of two separate lymph node stations on one side of the diaphragm
Stage III	Spread to both sides of the diaphragm, involving lymph nodes, spleen, tonsils, and Waldeyer ring
Stage IV	Extralymphatic dissemination (bone marrow, liver, lung, bone, skin, pleura)

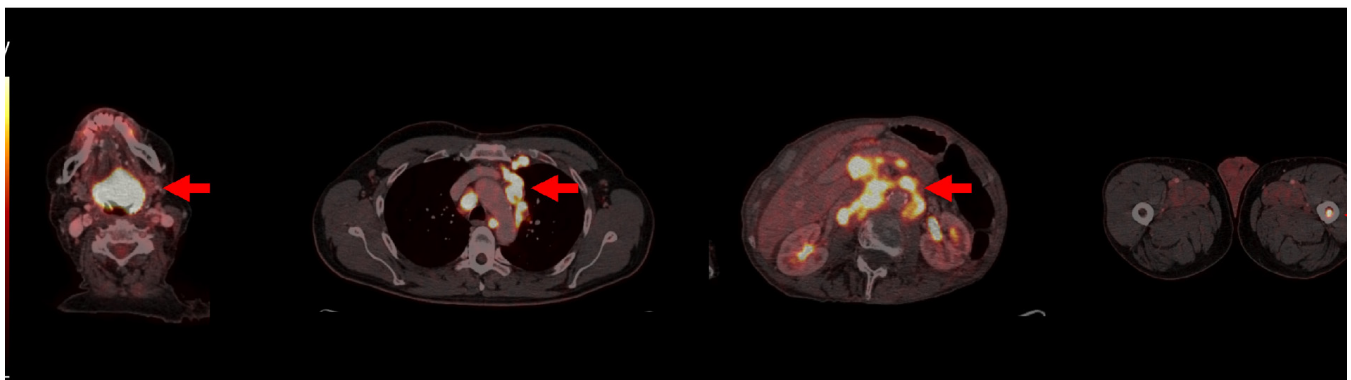
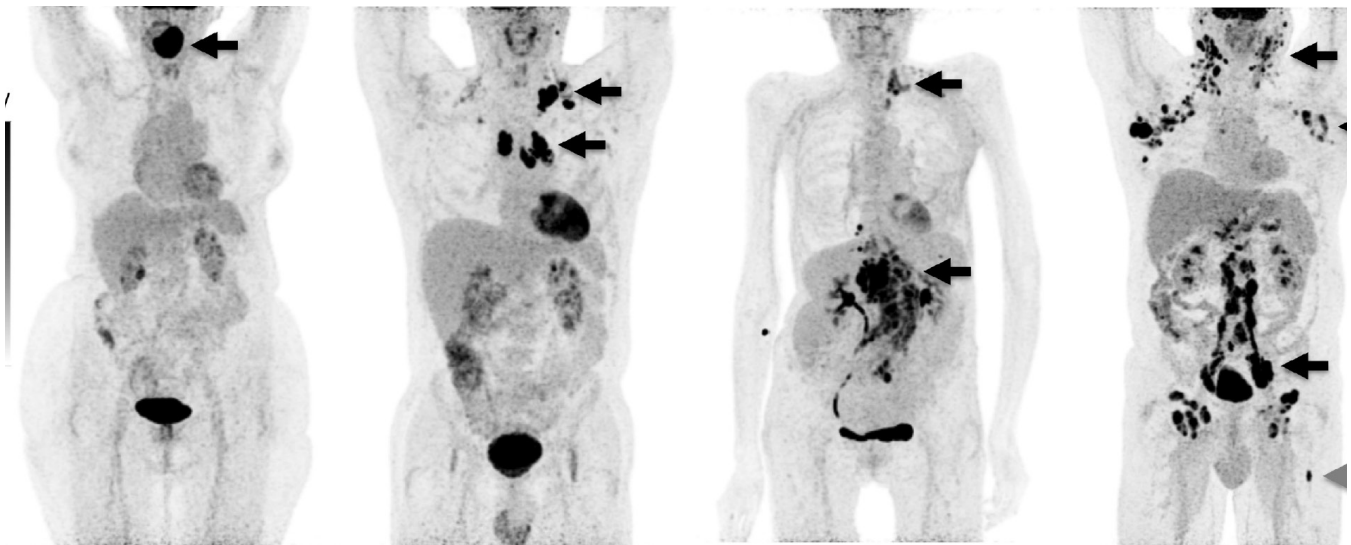


Fig.1:

involvement confined to a single lymph node region or extranodal site (stage I), involvement of more lymph node regions on one side of the diaphragm with or without limited contiguous extranodal involvement (stage II), lymph node involvement on both sides of the diaphragm (stage III), and extensive extranodal involvement (stage IV). Black arrows denote lymph node involvement. Grey arrow denotes bone marrow involvement. Lower panel: Representative transaxial slices of areas of lymph node (stage I–III) and bone marrow involvement (stage IV). SUV, Standardized Uptake Value.

Staging of NHL in pediatric patients

Ann Arbor Staging System

pediatric NHL is staged according to the Murphy stage

Stage I: Stage I disease involves a single tumor (extranodal) or single anatomic area (nodal), excluding the abdomen and mediastinum. Features of stage II to IV disease described below must be absent.

Stage II: Stage II – Stage II disease is designated by any of the following:

- Single extranodal area plus regional lymph nodes
- Two single extranodal tumors on the same side of the diaphragm with or without regional lymph nodes
- Primary gastrointestinal tumor (completely resected) with or without mesenteric lymph nodes

Stage III: Stage III – Stage III disease is designated by any one of the following:

- Primary intrathoracic (mediastinal, thymic, pleural) disease
- Two extranodal sites on opposite sides of the diaphragm
- Extensive primary intra-abdominal disease
- Two or more nodal areas on opposite sides of the diaphragm
- Any paraspinal or epidural tumors

Stage IV : Stage I disease involves a single tumor (extranodal) or single anatomic area (nodal), excluding the abdomen and mediastinum. Features of stage II to IV disease described below must be absent.

18F-FDG PET/CT has variable sensitivity to detect the tumor depending on histological subtype of lymphoma. In general PET/CT has high sensitivity in the 3 major classes of this malignancy in clinical practice (diffuse large and follicular lymphomas and HD) (6).

A: HD:

The different histological subtypes of HD all have substantial FDG uptake.

B: NHL:

Most indolent lymphomas has low FDG avidity; however, DLBCL, follicular, burkitt and mantle cell lymphomas routinely have high FDG avidity. Marginal zone lymphomas, chronic lymphocytic leukemia/small lymphocytic lymphomas and lymphoblastic lymphomas typically have limited FDG avidity (6).

C: Bone marrow involvement and splenic disease:

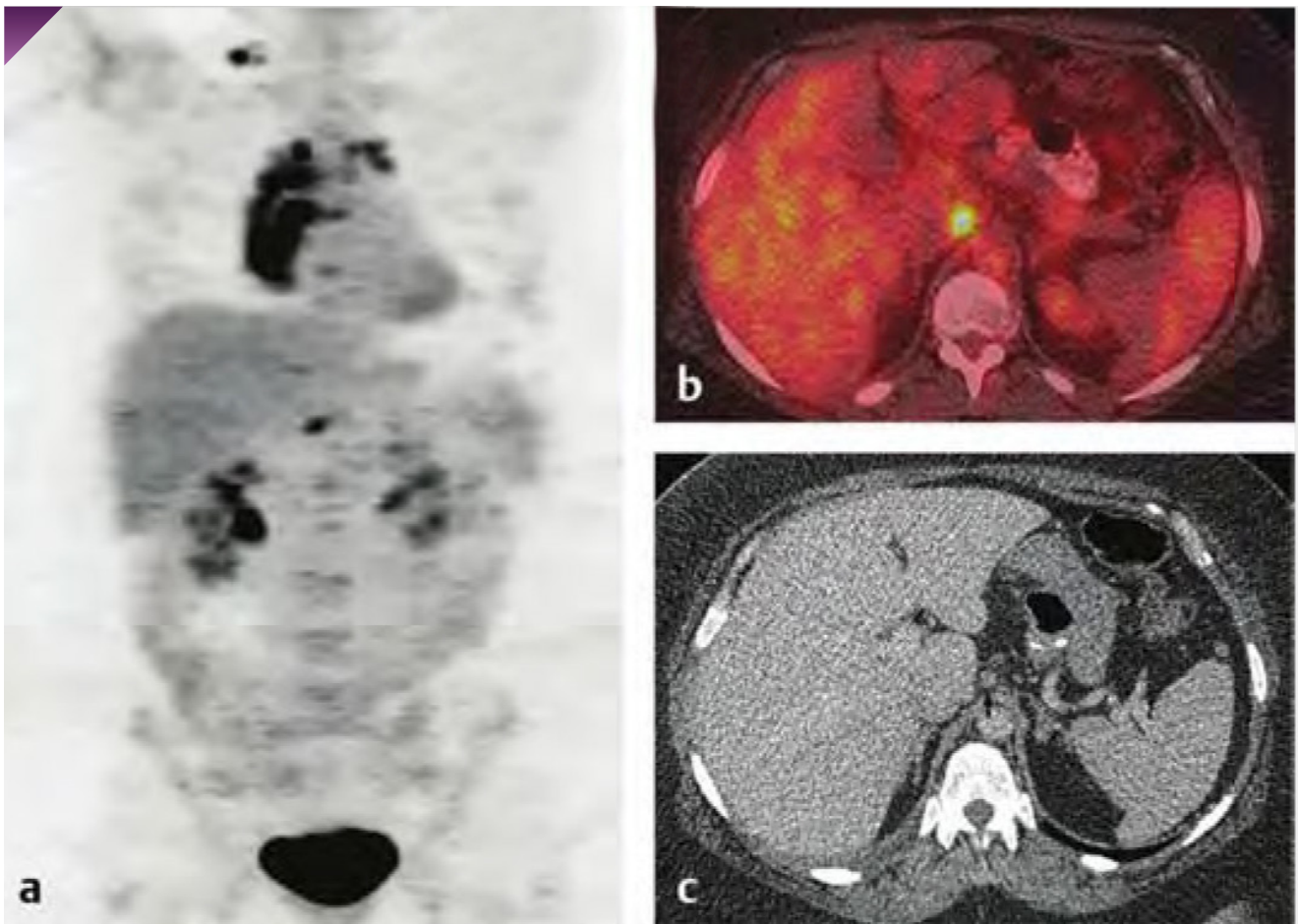
18 F-FDG PET/CT can potentially replace bone marrow biopsy (BMB) in newly diagnosed HD and DLBCL. 18 F-FDG PET/CT is able to detect sites of bone marrow involvement not sampled with iliac crest biopsy. The Lugano classification indicates that if PET/CT is performed in HD, a BMB is not necessary. In DLBCL, a positive FDG PET/CT finding indicates bone or bone marrow involvement but a negative scan requires BMB. (A BMB is only needed for DLBCL if PET is negative or identifying discordant histology is relevant in patient's management). BMB is recommended for all other lymphomas (5,6,7). On the other hand, 18 F-FDG PET/CT can miss low-volume involvement (typically < 20% of the marrow) or coexistent low-grade lymphoma in DLBCL. About splenic involvement, 18 F-FDG PET/CT is more accurate for detecting focal splenic involvement than gallium scan or CT (97% accurate in HD) (6).

Comparison to other Modalities

18 F-FDG PET/CT (with low-dose non-enhanced CT) is more sensitive and specific than contrast-enhanced CT for both nodal and extra nodal disease. Also, 18 F-FDG PET/CT is superior to gallium scan for both initial staging and follow-up of lymphoma (6,10).

Staging

18 F-FDG PET/CT is a standard modality for staging both HD and NHL. In HD, National Comprehensive Cancer Network (NCCN) guidelines recommend baseline 18 F-FDG PET/CT as an essential test. 18 F-FDG PET/CT can be of value in any stage in HD, but it is most useful in stage I and II disease where a change in stage will alter disease management. The staging study can also serve as a baseline for comparison with post-therapy studies. In NHL, NCCN guidelines recommend baseline 18 F-FDG PET/CT as an essential test in DLBCL and AIDs related B-cell lymphoma and as a useful test in selected cases in many other NHL subtypes. Staging 18 F-FDG PET/CT is also necessary as a baseline test if PET/CT is to be used to monitor response to treatment (4,6,7,10).

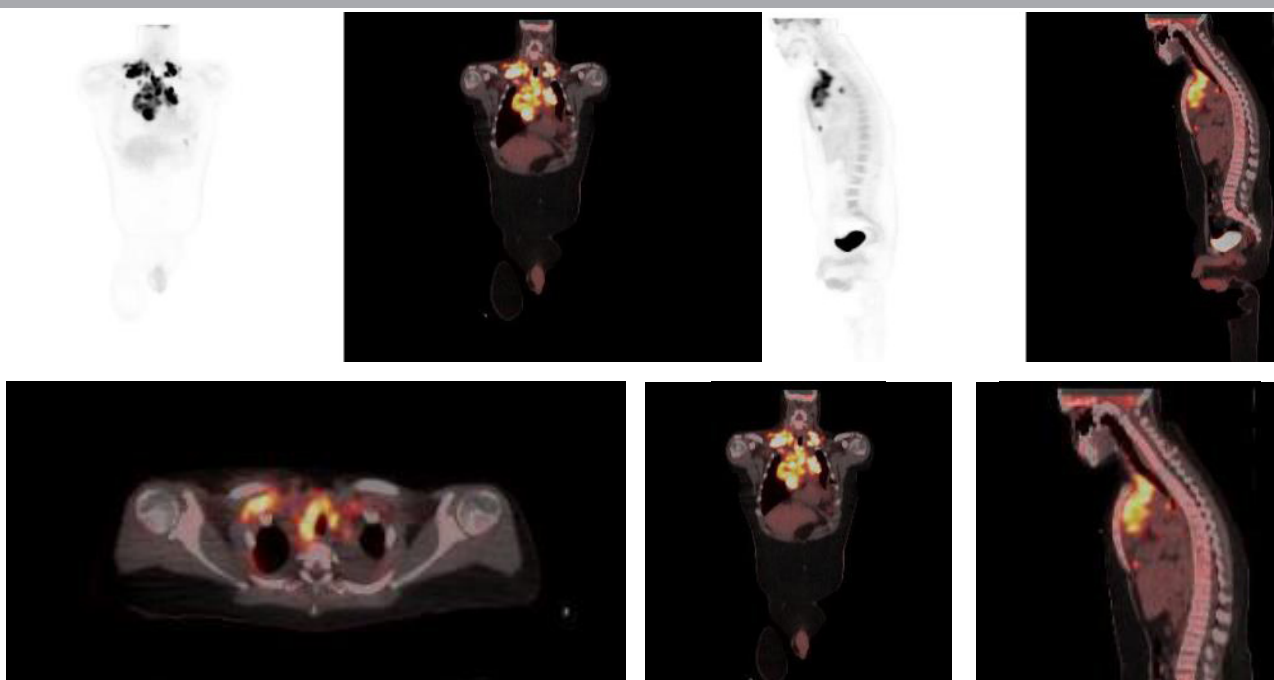


Interim PET/CT

A: HD: The early PET monitoring of lymphoma therapy (interim-PET) can be used to predict the relapse rate (prognosis). 18 FDG PET/CT is capable of assessing therapy response after two cycles of chemotherapy. In stages IA-IIA (favorable disease of HD) the role of interim PET is less clear than advanced stages. In stages I-II (unfavorable disease) and stages III & IV, the general aim in interim PET study is to deescalate therapy for those with a good early PET response or escalate therapy in poor PET responders (4,6).

B: NHL: The routine clinical use of interim PET/CT was not recommended in DLBCL. It may have some prognostic value but studies have not shown any benefit; However, PET/CT remains superior to CT assessment in this setting and can be helpful for mid-treatment imaging (6).

a



b

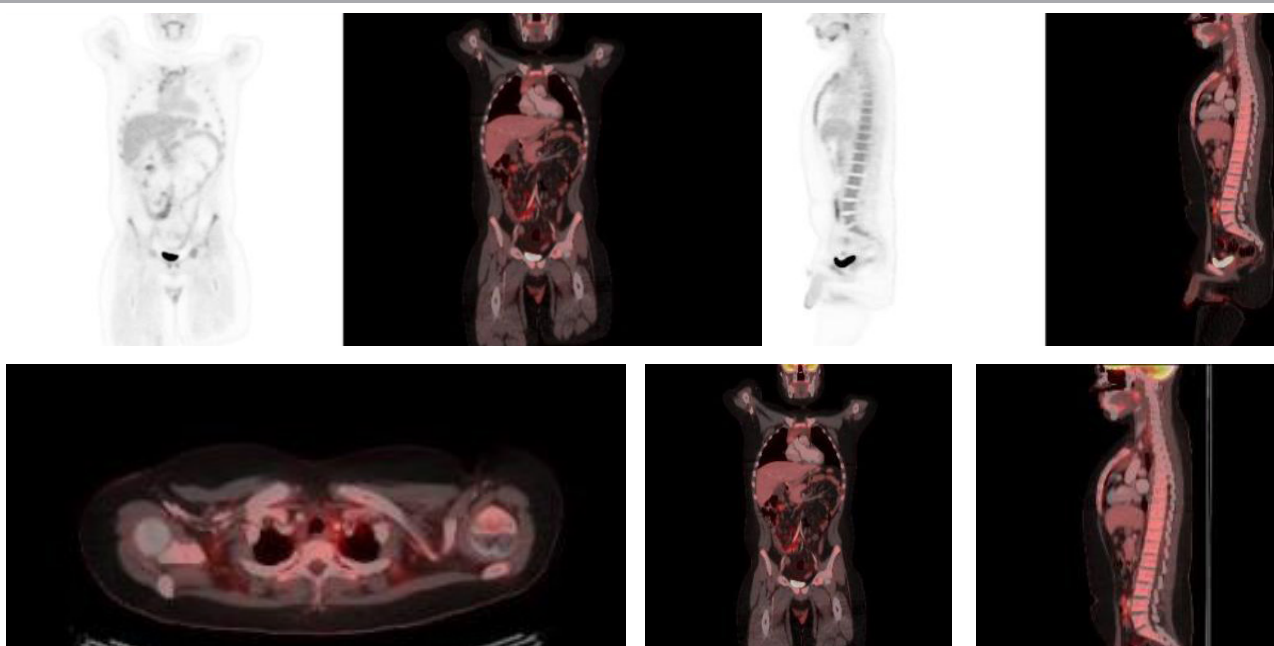


Fig.3:

12 years old boy with Hodgkin lymphoma baseline(a) and after two dose of chemotherapy (b) showing a complete metabolic response with Deauville score 2.

Evaluation of final response to treatment

Incorporation of FDG-PET/CT for end-of-treatment response assessment has improved the ability to understand response to primary therapy, as it can better discriminate between active lymphoma and post-treatment fibrotic tissue. Deauville five-point scale incorporating the Deauville criteria (DC) is recommended for response assessment in international guideline (4,5,6,7). The DC have been validated in most lymphoma subtypes and can indicate complete response (CR), partial response (PR), stable disease (SD) or progressive disease (PD) (5).

Deauville Score

The Deauville Criteria uses a five point scale based on visual analysis of FDG PET/CT imaging of the site of initial (pre-treatment) lymphoma:

Score	Definition
1	No uptake
2	uptake ≤ mediastinum
3	uptake ≤ mediastinum but ≤ liver
4	Moderately increased uptake compared to the liver
5	Moderately increased uptake compared to the liver and/or new lesions
6	New areas of uptake unlikely to be related to lymphoma

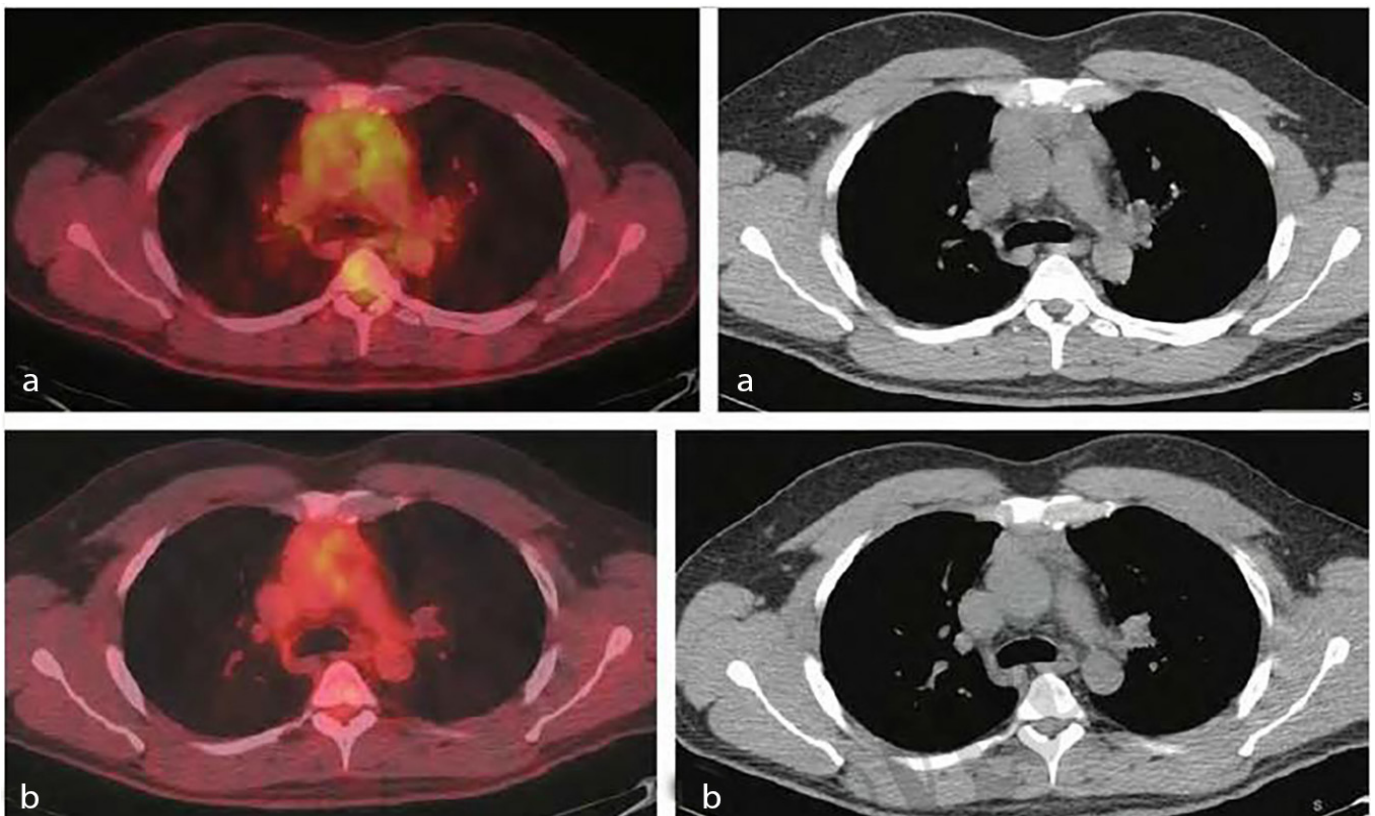


Fig.4:

Lymphoma therapy response, Axial PET/CT (a) and CT (b) demonstrate an anterior mediastinal mass in a patient with hodgkin's disease post therapy. This has uptake greater than the liver and should be interpreted as residual disease. After further therapy the degree of FDG uptake is equal to the mediastinum (c) and the mass is smaller on CT (d). This can be interpreted as complete metabolic response to treatment.

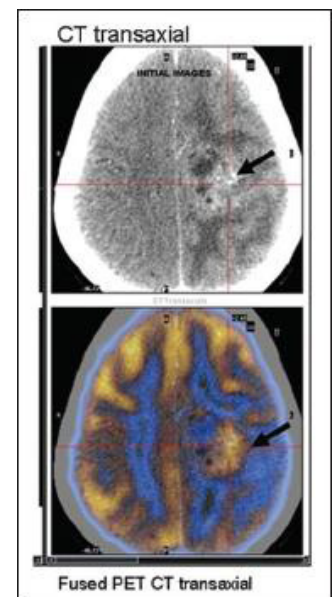
Brain tumors

Introduction

Pediatric central nervous system (CNS) tumors are the most common solid tumors in children and comprise 15% to 20% of all malignancies in children as well as No. 1 cause of death among all childhood cancers (13). Pediatric brain tumors are more likely to be lower grade glial tumors or tumors arising from primitive, embryonal cells of the central nervous system, so astrocytomas and medulloblastomas are the most common brain tumors in children (12,13). WHO classification uses specific morphological features—nuclear atypia, mitoses, microvascular proliferation, and necrosis—to grade gliomas according to degree of malignancy. Analysis of the most malignant region of the tumors establishes grading: low grade or WHO grades I and II, and high grade or WHO grades III (anaplastic tumor) and IV (glioblastoma) (13).

Roles of 18F-FDG PET study in brain tumors

Because of the high physiologic FDG uptake in grey matter and low tumor to background ratio, FDG PET imaging in brain tumors is challenging; however, currently 18F-FDG is the most widely available PET tracer for body imaging and brain imaging in our country. Malignant brain tumors, like many other soft-tissue tumors, show increased glucose metabolism, which is shown on FDG-PET studies. Routine PET study is not indicated in all newly diagnosed brain tumors but it can be helpful in different situations. Clinical application of PET imaging in brain tumors has demonstrated that it is helpful in tumor grading, establishing prognosis, defining targets for biopsy, and planning resection. Radiolabeled amino acids [18 F (FDOPA); 11C-methionine (MET), 18F-fluoroethyltyrosine (FET)] have become preferred PET tracers in neuro-oncology, and the RANO (Response Assessment in Neuro-Oncology) group recommends the use of amino acid PET at all stages of patient management. (7,14). Using Radiolabeled amino acids will be promising in future in brain tumor management in our country.

**Fig.5:**

FDG PET/CT images in a 15-year-old girl suspected to have recurrent glioma. Fused FDG PET/CT transaxial images clearly demarcate the tumor site from surrounding edema.

18F-FDG PET/ CT can be helpful in these clinical applications in brain tumors

- **Determining the best biopsy site for optimal grading of the tumor:** FDG-PET can be used to define the most metabolically active targets for stereotactic biopsy. This in turn can improve diagnostic accuracy and reduce the number of biopsy samples required.

- **Metabolic grading of the tumor:** The degree of glucose metabolism correlates with prognosis and outcome of these patients
- **Evaluating possible transformation of a low grade glioma to a high grade tumor:** Increased FDG uptake in the previously diagnosed low grade tumor is suggestive of malignant transformation.
- **Differentiation of radiation necrosis versus tumor:** it is often difficult to differentiate tumor recurrence versus radiation necrosis on CT or MRI as both entities demonstrate contrast enhancement. 18F-FDG PET is valuable in this situation.

Sarcomas

Introduction

Sarcomas are a rare and heterogeneous group of malignant tumors of mesenchymal origin that comprise less than 12 percent of pediatric cancers. Approximately 80 percent of new cases of sarcoma originate from soft tissue, and the rest originate from bone. Soft tissue sarcomas are further delineated into rhabdomyosarcomas (45%), which affect young children and non-rhabdomyosarcomas (55% including Malignant peripheral nerve sheath tumor – Synovial sarcoma – Fibrosarcoma – Epithelioid sarcoma), which are most common in adolescents (The most common bone sarcomas are osteosarcomas and Ewing’s sarcoma. (15,16).

Staging

The Musculoskeletal Tumor Society (MSTS) staging system is most often used for bone sarcomas and was developed by Enneking at the University of Florida. The MSTS staging system characterizes non-metastatic malignant bone tumors by grade (low-grade [stage I] versus high-grade [stage II]) and further subdivides these stages according to the local anatomic extent (intracompartmental [A] versus extracompartmental [B]). For bone tumors, the compartmental status is determined by whether the tumor extends through the cortex of the involved bone; the majority of high grade osteosarcoma are extracompartmental. Patients with distant metastases are categorized as stage III (16).

Osteosarcoma

Osteosarcoma is the most common bone tumor of children and young adults, and 80% of osteosarcomas present between the ages of 5 and 25 years. OS occurs predominately in the metaphyses of the long bones of the extremities. The most common site of metastatic disease is lung. Less commonly, 10–20% of metastases are in bone, but lymph node metastatic disease is rare (16)

Roles of 18F-FDG PET study in osteosarcoma

The primary uses of 18 F-FDG PET/CT as follows: (6)

- **Staging:**
-18 F-FDG PET/CT is more sensitive and accurate than bone scan in detecting bone METs of osteosarcoma.
- **Tumor grading**
-In known sarcomas, the degree of FDG uptake (baseline SUV) at the time of diagnosis is adverse prognos-

tic factor for patient outcome.

- **Guiding biopsy in heterogeneous tumors**

-Determining the areas with highest metabolic activity for biopsy and so highest diagnostic yield.

- **Therapy monitoring**

18 F-FDG PET/CT predicts tumor response to preoperative neoadjuvant chemotherapy and eventual outcome.

- **Diagnosis of local recurrence**

18 F-FDG PET/CT is more accurate than CT or MRI for the detection of local recurrence in patients with osteosarcoma, as CT and MRI have difficulties in differentiating post therapy tissue changes and fibrosis from local recurrence.

Guidelines from the NCCN suggest a PET scan and/or bone scan in the workup of a suspected osteosarcoma. Imaging guidelines from the Children's Oncology Group Bone Tumor Committee recommend radionuclide bone scan and/or PET scan for whole body staging. This guideline recommend Whole body Technetium bone scintigraphy (with SPECT recommended) and/or FDG-PET in these cases: (17)

1. At presentation and repeated prior to surgery/local control
2. Surveillance on chemotherapy: Technetium bone scintigraphy (add SPECT of lungs if pulmonary metastases suspected) or FDG-PET (if disease positive on prior FDG-PET) at the end of cytotoxic chemotherapy, sooner if symptoms or abnormal imaging (and surgical or other intervention contemplated)
3. Surveillance post-chemotherapy: Technetium bone scintigraphy or FDG-PET (if disease positive on prior FDG-PET) if symptoms or abnormal imaging (and surgical or other intervention contemplated).

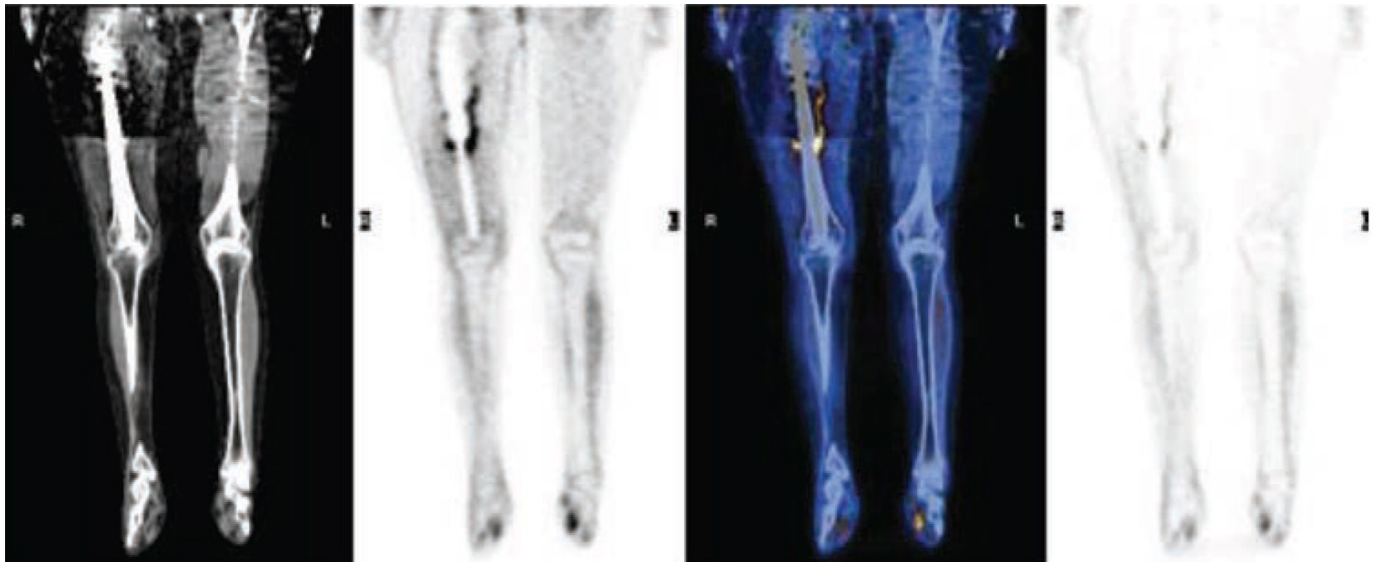


Fig 6:

A 16-year-old girl with recurrent osteosarcoma after a limb-sparing procedure. PET/ CT images (from left to right, CT, FDG] PET, fusion, and FDG PET non-attenuation corrected images) show increased uptake along the border of the prosthesis.

Ewing’s sarcoma

Ewing sarcoma (ES) and peripheral primitive neuroectodermal tumor (PNET) are actually part of a spectrum of neoplastic diseases known as the ES family of tumors (EFT). The EFT can develop in almost any bone or soft tissue but is most common in the pelvis, axial skeleton, and femur. Metastatic disease is common; approximately one quarter of patients have metastatic disease at diagnosis. Lung, bone and bone marrow are the most common sites of metastases. The key prognostic factor in Ewing sarcoma is the presence or absence of metastases (18)

Introduction

18 F-FDG PET/CT is used for staging, restaging and assessment of therapy response in patients with ewing’s sarcoma. (6)

- Staging (Identification of sites of disease by 18 F-FDG PET/CT and localization of metastases affects staging and initial risk stratification.
- Assessment of therapy response
- Evaluation of recurrence

Children’s Oncology Group Bone Tumor Committee recommend Whole body Technetium bone scintigraphy and/or FDG-PET in these cases: (17)

1. At presentation and prior to local control: Technetium bone scintigraphy and/or FDG-PET (recommended at presentation, particularly if primary bone tumor negative on bone scintigraphy).
2. Surveillance on chemotherapy: Technetium bone scintigraphy (if disease positive on prior bone scintigraphy) or FDG-PET (if disease positive on prior FDG-PET and bone scan-negative) recommended: At the end of cytotoxic chemotherapy and sooner if symptoms or abnormal imaging (and surgical or other intervention contemplated)
3. Surveillance postchemotherapy: Technetium bone scintigraphy (if positive on prior scans) or FDG-PET (if positive on prior scans and bone scan-negative) if symptoms or abnormal imaging AND surgical or other intervention contemplated.

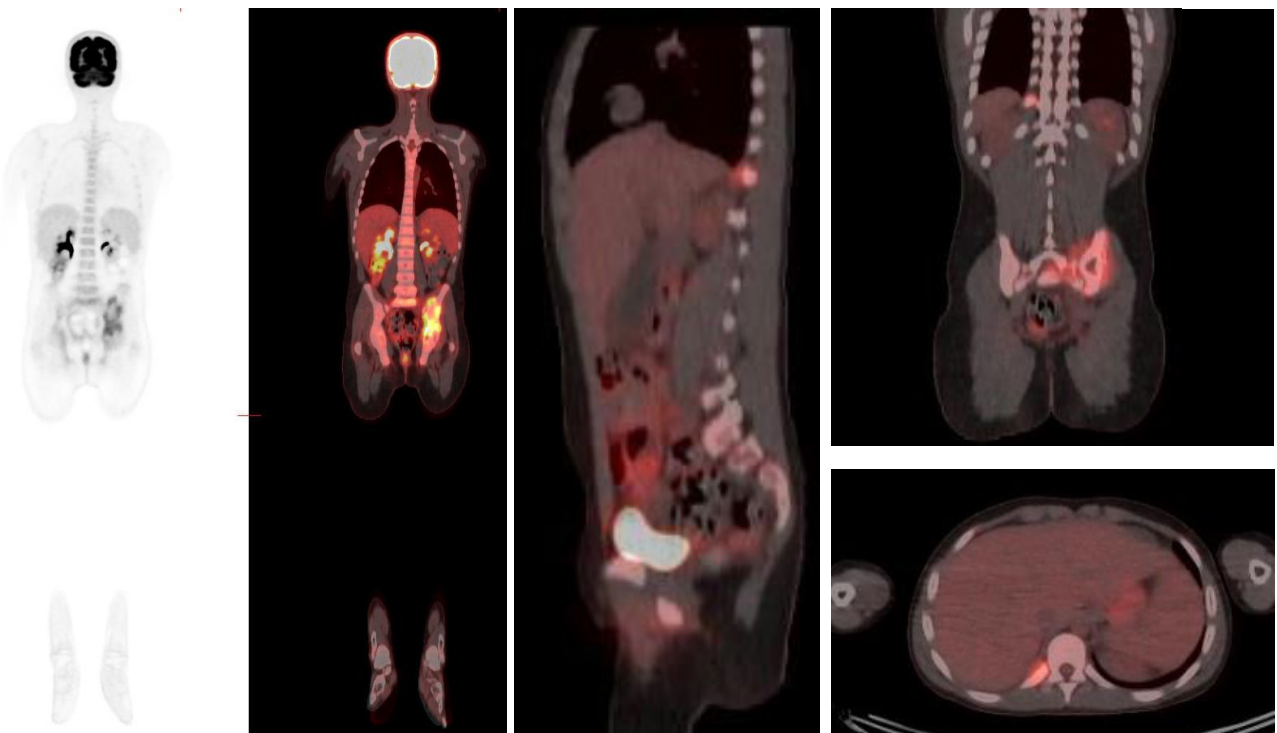


Fig 7:

14 years old patient with Ewing sarcoma in the left pelvis. PET scan was done for staging and showed a lesion in the right 10th rib suggestive of metastasis (upstaged the disease).

Rhabdomyosarcoma

Rhabdomyosarcoma is the most common soft tissue malignancy of childhood. The peak incidence occurs between 3 and 6 years of age. The most common anatomic locations are the head, particularly the orbit and paranasal sinuses, the neck, and the genitourinary tract (19).

Roles of 18F-FDG PET study in rhabdomyosarcoma

18F FDG PET/CT does not yet have an established role in rhabdomyosarcoma but since these tumors are metabolically active, defined roles for PET/CT are likely to develop in the future. About 4% of rhabdomyosarcomas will present with widely metastatic disease and unknown primary site, PET/CT allows examination of the whole body in one setting and can be helpful in detecting lymph node and distant metastatic disease. NCCN guidelines state that PET imaging may be useful in initial staging because of the possibility of nodal metastases and the appearance of unusual sites of initial metastatic disease in adult patients (6, 4). Overall 18F FDG PET/CT can be helpful in these cases:(6)

- Unknown primary site of metastatic rhabdomyosarcoma
- Staging: Evaluation of lymph node involvement and distant metastasis
- Evaluation of response to treatment: FDG avidity of primary and metastatic site after chemotherapy appears to reflect tumor viability
- Evaluation of recurrence

Neuroblastoma

The term neuroblastoma is commonly used to refer to a spectrum of neuroblastic tumors (including neuroblastomas, ganglioneuroblastomas, and ganglioneuromas) that arise from primitive sympathetic ganglion cells and, like paragangliomas and pheochromocytomas, have the capacity to synthesize and secrete catecholamines. Neuroblastoma is the most common extracranial solid malignant tumor in children. The mean age of patients at presentation is 20 to 30 months, and it is rare after the age of 5 years.

The most common location of neuroblastoma is the adrenal gland. Other sites of origin include the paravertebral and presacral sympathetic chain, the organ of Zuckerkandl, posterior mediastinal sympathetic ganglia, and cervical sympathetic plexuses. Neuroblastoma metastasizes by both lymphatic and hematogenous routes. Hematogenous spread extends most often to bone, bone marrow, skin, and liver. Regional and non-regional lymph node metastasis is also common (9,20).

Roles of 18F-FDG PET study in neuroblastoma

The current standard for staging and restaging NB is 123I/131I-metaiodobenzylguanidine (MIBG) scintigraphy; however, Neuroblastomas are metabolically active tumors and 18F FDG PET/CT can be helpful in specific situations. 18F FDG PET/CT have limited value in identifying cranial lesions or marrow involvement because of physiologic uptake in the brain and marrow. So currently, the primary role of 18-F FDG PET in

neuroblastoma seems to be in the evaluation of known or suspected neuroblastomas that do not demonstrate MIBG uptake. 18 F-FDG–PET has also been suggested as a complementary rather than a substitute exam for MIBG scintigraphy in NB staging and treatment monitoring (8,9)

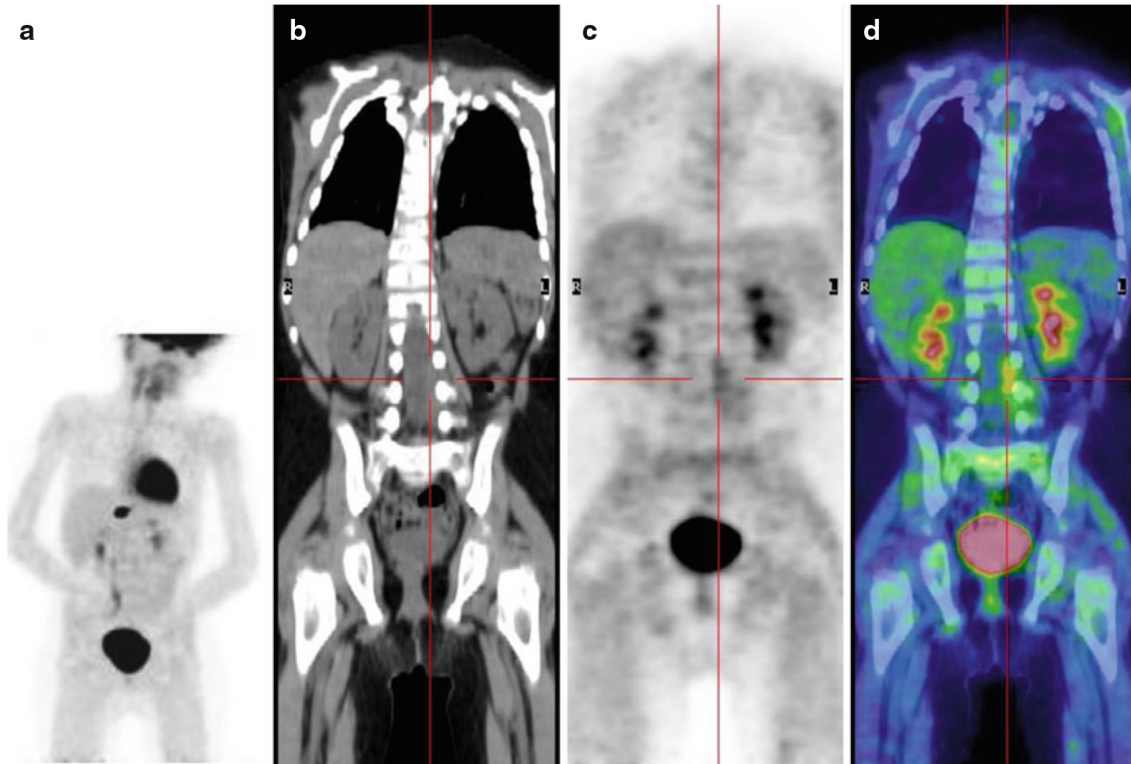


Fig 8:

A 5-year-old boy treated 3 years earlier for a thoracic neuroblastoma, stage IV, . Following the development of pain in his right leg and difficulty walking, he underwent MRI, which showed the presence of epidural tissue in the L3–L5 vertebral canal. The bone marrow aspiration was negative, urinary catecholamines were normal, and 123 I-MIBG scintigraphy was negative. (a) MIP; (b) coronal CT, (c) PET, (d) PET/CT fusion images show inhomogeneous 18 F-FDG uptake in the left L3–L5 vertebral canal

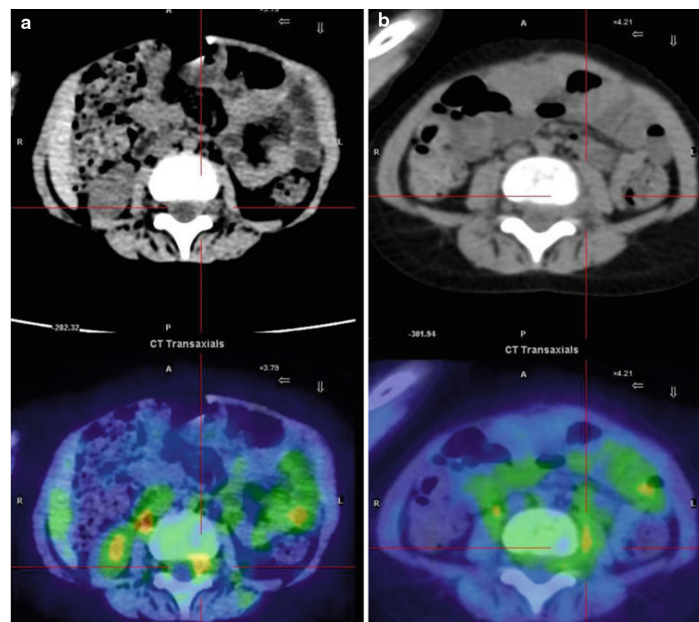


Fig. 9:

Same patient as in Fig 8 Axial CT and PET/CT fusion images of the intra-canal (a) and extra-canal (b) lesion. The patient underwent chemotherapy followed by interleukin-2 and isotretinoin treatment

References:

1. Guidelines for 18F-FDG PET and PET-CT imaging in pediatric oncology, EANM 2008.
2. Overview of Hodgkin lymphoma in children and adolescents, Uptodate 2017.
3. Overview of non-Hodgkin lymphoma in children and adolescents, Uptodate 2018.
4. NCCN practice guidelines.
5. The Deauville scale and Lugano criteria. ACNM Spotlights, Saabry Osmany.
6. Eugene lin, abass alavi. PET and PET/CT: A clinical guide. 3rd edition. Thieme;2019
7. Mohsen Beheshti, Werner Langsteger, Alireza Rezaee, Markus Raderer and Niklaus Schaeffer. PET/CT in cancer an interdisciplinary approach to individualized imaging. Elsevier; 2018.
8. Angelina Cistaro. Atlas of PET/CT in pediatric patients. Springer;2014
9. Richard L. Wahl. Principles and practice of pet and PET/CT. 2nd edition. Lippincott williams and wilkins; 2009.
10. Yuan, Zhang, Li & Yang. PET/CT application in pediatric oncology. Future Medicine; 2012
11. Bruce D chosen and et al. Recommendations for Initial Evaluation, Staging, and Response Assessment of Hodgkin and Non-Hodgkin Lymphoma: The Lugano Classification;, J Clin Oncol. 2014 Sep 20; 32(27): 3059–3067.
12. Epidemiology of central nervous system tumors in children, Uptodate 2017.
13. The 2016 world health organization classification of tumors of the central nervous system.
14. Nathalie L. Albert, et al. Response Assessment in Neuro-Oncology working group and European Association for Neuro-Oncology recommendations for the clinical use of PET imaging in gliomas. Neuro Oncol. 2016 Sep; 18(9): 1199–1208.
15. Clinical presentation, histopathology, diagnostic evaluation, and staging of soft tissue sarcoma, uptodate 2019.
16. Osteosarcoma: Epidemiology, pathogenesis, clinical presentation, diagnosis, and histology, uptodate 2018.
17. Meyer JS and et al. Imaging guidelines for children with Ewing sarcoma and osteosarcoma: a report from the Children's Oncology Group Bone Tumor Committee. Pediatr Blood Cancer. 2008 Aug;51(2):16370-.
18. Clinical presentation, staging, and prognostic factors of the Ewing sarcoma family of tumors, upodate 2018.
19. Rhabdomyosarcoma in childhood and adolescence: Epidemiology, pathology, and molecular pathogenesis, uptodate 2017
20. Clinical presentation, diagnosis, and staging evaluation of neuroblastoma, uptodate 2018.

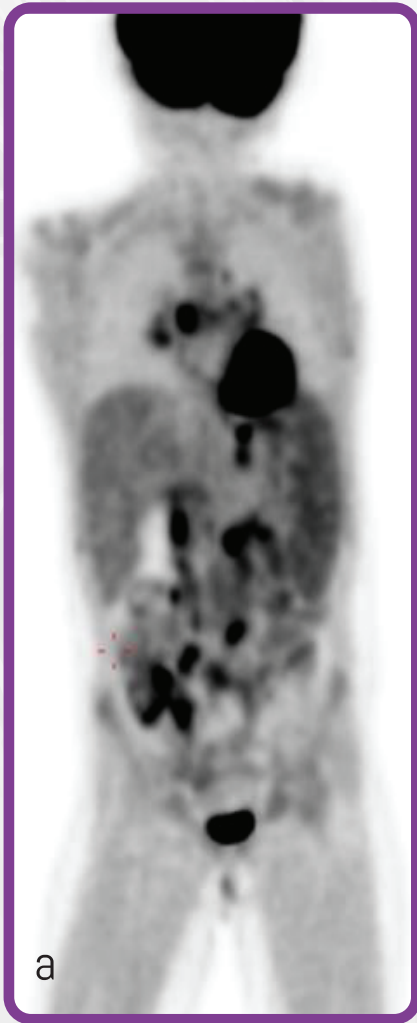
مرکز پت سی تی

بیمارستان خاتم الانبیاء (ص)

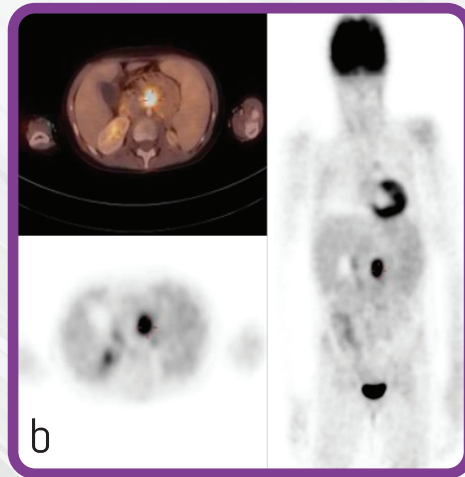


A case presentation

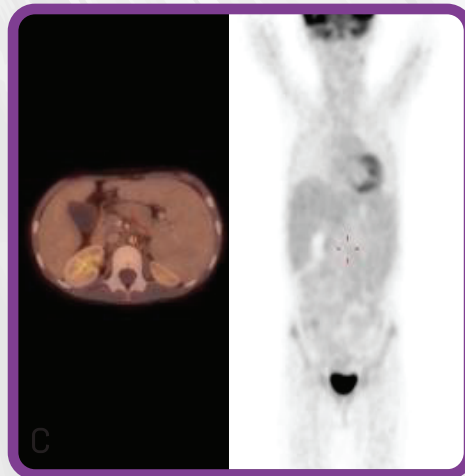
A 6-year old following heart transplant; biopsy proven PTLD in bowels.
 Baseline PET/CT showed multiple hypermetabolic lesions in the abdomen (a).
 PET/CT after therapy showed a good response but there was a focal uptake in the abdomen corresponding to a hypermetabolic lymph node (b).
 (The lesion disappeared after changing the chemotherapy regimen (c).



Before Therapy



After Therapy



After Changing the Regimen
(2 more chemo)

Post-Transplantation Lymphoproliferative Disorders (PTLD) are a heterogeneous group of diseases that occur after transplantation ranging from EBV-driven polyclonal proliferation similar to infectious mononucleosis, to monomorphic proliferations that may be indistinguishable from aggressive types of lymphoma. It is very common in pediatric oncology especially during the first year following transplantation. **18F-FDG PET/CT** is a very useful method for diagnosis, assessment of the extent of disease, guide for biopsy and evaluation of treatment response.



Address: Khatam PET/CT center, Khatam ol
Anbia hospital, Rashid Yasemi St. , Vali- Asr Ave.,
Tehran, 1996835911, Iran.
Tel : +98 21 83557080 - +98 21 83557070

www.petctkhatam.ir